



## Giant osteoma of the occipital bone: A case report

Benson Samuel<sup>1</sup>, Udoinyang Clement Inyang<sup>2</sup>

<sup>1</sup>Department of Radiology, University of Uyo, Akwa Ibom State, Nigeria

<sup>2</sup>Department of Orthopaedics, University of Uyo, Akwa Ibom State, Nigeria

### Abstract

Osteomas are benign, slow-growing osteogenic tumors commonly occurring in the craniofacial bones. They are usually asymptomatic and can be discovered in routine clinical and radiographic examination. In this paper, we present a large solitary osteoma located in the occipital region causing aesthetic deformity and headache in a 22-year-old woman. Patient underwent radiographic examination with computed tomography followed by surgical excision and histopathological analysis.

**Keywords:** Occipital, Osteoma, Gardner's syndrome, Cosmetic deformity.

### Introduction

Osteoma is a benign bone tumor characterized by compact or cancellous bone proliferation. The aetiology of osteomas is equivocal. However, congenital anomalies, trauma and infection have been implicated.<sup>1-3</sup>

It has been reported that osteomas can occur at any age and that males and females are equally affected.<sup>4,5</sup> However, a female predilection has also been reported.<sup>6,7</sup> Osteomas are slow-growing lesions and patients are usually asymptomatic. However, cosmetic deformity occurs when they reach a large size and complete surgical excision may be required.<sup>4,5</sup>

Occipital osteomas are rare.<sup>4-6</sup> Computed tomography with 3-D volume rendering is the imaging modality of choice. Imaging with CT can help exclude involvement of the inner table of the skull and intracranial extension of tumour.<sup>4,7-10</sup>

We present a case of a slow-growing, large giant occipital osteoma in a 22-year-old female presenting with headache and cosmetic deformity of

15 years duration.

### Case Report

A 22-year-old woman was referred to the Radiology Department with a complaint of occasional headache and a continuous slow-growing mass lesion on the left occipital aspect of her skull of 15 years duration. She has been aware of the slow but steady increase in the size of the lesion over the past fifteen years. She had no previous facial trauma, and her medical history was not contributory. Clinical examination was unremarkable. The lesion was hard and non-fluctuant on palpation.

CT scan revealed (Fig.1-6) an inverted cup-shaped hyperdense mass lesion overlying the left occipital bone with an attenuation of 1641.9HU. It measured (15.1 x 14.4 x 15.6) cm in CC x TR x AP dimensions. The lesion had linear foci of hypodensity within it. There was no enhancement of the lesion on intravenous contrast administration. The inner table of the skull was not involved. No intracranial involvement was seen.

These clinical and radiographic findings were sufficiently supportive of the working diagnosis of giant occipital osteoma. There were no features of Gardner's syndrome.

Due to the cosmetic deformity, the patient was

**Corresponding Author: Dr. Benson Samuel**

Department of Radiology,  
University of Uyo, Uyo, Akwa Ibom State, Nigeria.  
E-mail: sambeesmb@yahoo.com,  
Phone Number: +234-----

prepared for surgery. The lesion was successively excised with no post-operative sequelae. The histopathologic diagnosis confirmed the clinical and radiographic diagnosis of giant occipital osteoma.

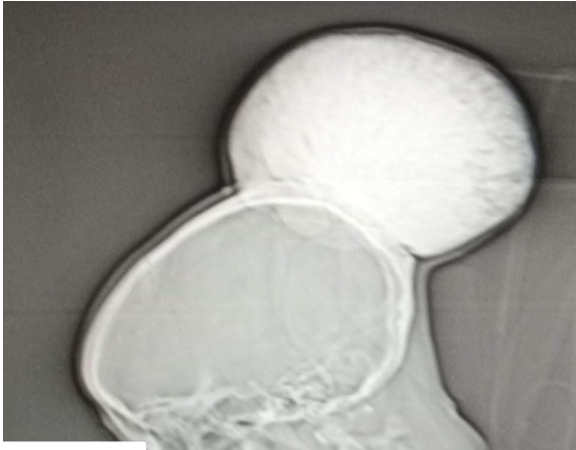


Figure 1

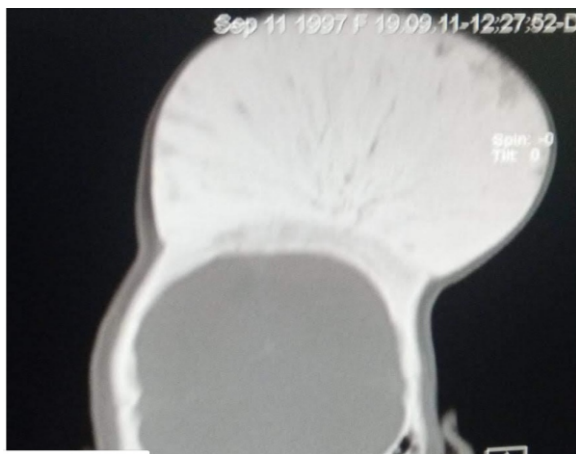

Figure 2

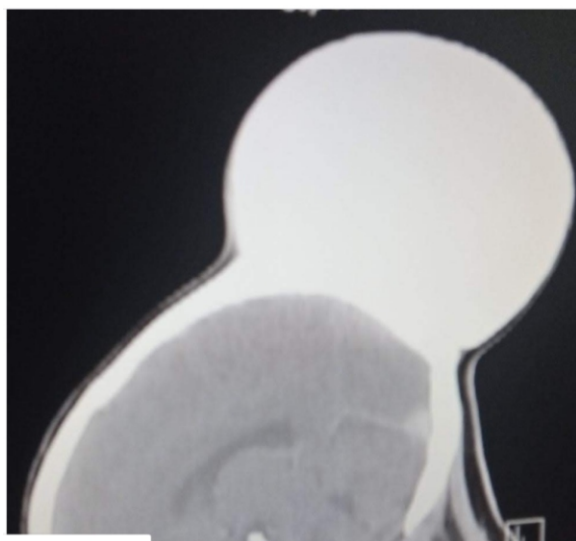

Figure 3

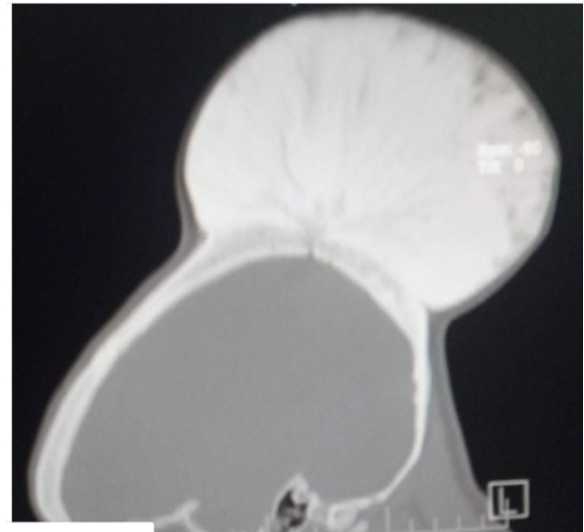

Figure 4

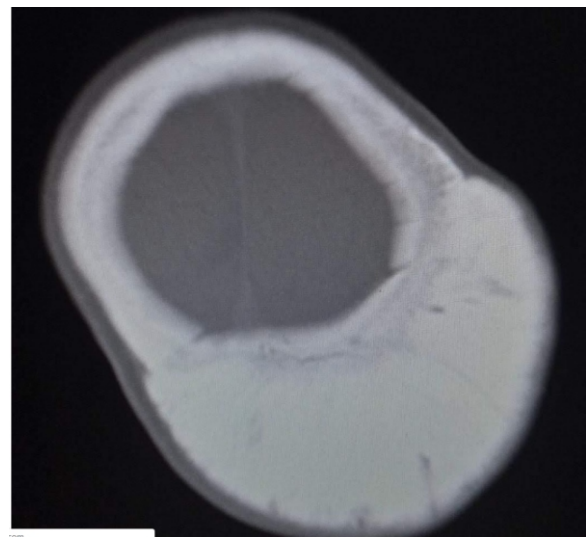


Figure 5

**Figure 1:** Scout CT image

**Figure 2:** Coronal CT image of the skull (bone window).

**Figure 3:** Sagittal CT image of the skull.

**Figure 4:** Sagittal CT image of the skull (bone window).

**Figure 5:** Axial CT image of the skull (bone window).

### Discussion

Osteomas are rare slow-growing benign bone tumor.<sup>4-6,11</sup> They commonly occur in the paranasal sinuses.<sup>12,13</sup> Involvement of the temporal and occipital squama is extremely rare.<sup>2-5,14</sup> It is frequently found in adults during the first 3 decades

of their lives. It affects both male and female equally<sup>4,5</sup> although other authors agree that it is mainly prevalent in women.<sup>6,15,16</sup> Osteomas larger than 3cm are termed giant osteomas.<sup>1,3-6</sup> They are also common in the frontoethmoidal region with above 40 cases reported in the literature.<sup>10-13,17</sup> Giant occipital osteoma are rare.<sup>3-6,11</sup>

Histologically osteoma can be divided into three types: mature, ivory and the mixed type.<sup>1,2,5</sup> The ivory type is composed of compact bone with almost no fibrovascular interstitial tissues. It mainly occurs in the frontal sinus and has a slow growth rate. On the other hand, the mature type is composed of mature cancellous bone and mainly occurs in the maxillary sinus and ethmoid sinus.<sup>10-13</sup> Mature type of tumor grows faster than the ivory type. Mixed osteoma is a mixture of cancellous and compact bone.<sup>1,3-7</sup> The latter was reported in the index patient. Several hypothesis have been put forward for the aetiology of osteoma but were regarded as hypothesis for the early detection of Gardner's syndrome of which osteoma is a component.<sup>16,18-22</sup>

Gardner syndrome is one of the polyposis syndromes. It is characterized by familial adenomatous polyposis, multiple osteomas (especially of the mandible, skull, and long bones), epidermal cysts, fibromatoses and desmoid tumors of mesentery and anterior abdominal wall. Other abnormalities include seen in Gardner's syndrome include supernumerary teeth, duodenal tumors / ampullary carcinoma and papillary thyroid carcinoma.<sup>23,24</sup>

Computed tomography is the imaging modality of choice for osteoma imaging.<sup>1,2-6</sup> The main differential diagnosis of osteoma includes osteosarcoma, osteoblastic metastasis, isolated eosinophilic granuloma, ossifying fibroma, Paget's disease (sclerotic), giant cell tumor, osteoid osteoma, hemangioma, calcified meningioma, and monostotic fibrous dysplasia.<sup>20-24</sup> Unlike malignant lesions, osteoma has a narrow zone of transition with the parent bone.<sup>25,26</sup>

Osteomas are resected if they become symptomatic or for cosmetic reasons especially for the giant ones.<sup>25-27</sup> The surgical target must be outlining normal cortical bone all around the lesion. Because these lesions are limited to the external cortex, finding a plane of cleavage between the osteoma and normal bone is not difficult.<sup>26-28</sup>

The prognosis of the osteoma may be considered the best in terms of cosmetic and curative aspects provided complete excision is undertaken.<sup>23-25</sup> Malignant transformation has not been reported yet.<sup>1,4-6</sup> The recurrence is also uncommon as only two cases have been reported so far.<sup>20,25-28</sup>

In young patients with skull osteomas, complete workup needs to be done to rule out Gardner syndrome by screening for the concurrent presence of intestinal polyps, soft tissue tumors, and dental abnormalities.<sup>16,18-20,29</sup>

### Conclusion

We have presented a case of a giant occipital osteoma in a 22-year-old female. The lesion had grown slowly for 15 years and cause headache and cosmetic deformity. Surgical excision was done with histopathological correlation. No significant postoperative sequelae occurred.

### References:

1. Munakomi S, Bhattarai B. A rare case report on suboccipital region benign giant osteoma. *Case Rep Neurol Med* 2016; 20:209-211.
2. Nishitani K, Okajima K, Tsuda T. A case of giant osteoma in the occipital bone. *Geka* 1990; 18:947-952.
3. Meher R., Gupta B., Singh I., Raj A. Osteoma of occipital bone. *Indian Journal of Surgery*. 2004;66(6):365-367.
4. Erten F, Hasturk AE, Pak I, Sokmen O. Giant occipital osteoid osteoma mimicking calcified meningioma. *Neurosciences*. 2011;16(4):363-365.
5. Nishitani K, Okajima K, Tsuda T. A case of giant osteoma in the occipital bone. *Shinkei Geka*. 1990;18(10):947-952.
6. De Praeter MP, Dua GF, Seynaeve PC, Vermeersch DG, Klaes RL. Occipital pain in osteoid osteoma of the atlas. A report of two cases. *Spine*. 1999;24(9):912-914
7. Ahmadi MS, Ahmadi M, Dehghan A. Osteoid osteoma presenting as a painful solitary skull lesion: a case report. *Iranian Journal of Otorhinolaryngology*. 2014;26(75):115-118.
8. Park SJ, Kim YH. A case of giant osteoma developed from the mastoid cortical bone. *Korean Journal of Audiology*.

- 2012; 16(2): 95–98. doi: 10.7874/kja.2012.16.2.95.
9. Carlos UP, De carvalho RWF, De Almeida AMG, Rafaela ND. Mastoid osteoma. Consideration on two cases and literature review. *International Archives of Otorhinolaryngology*. 2009;13:350–353.
  10. Sente M, Topolac R, Peić-Gavran K, Aleksov G. Frontal sinus osteoma as a cause of purulent meningitis. *Medicinski preglod*. 1999;52(3–5):169–172.
  11. Izci Y. Management of the large cranial osteoma: experience with 13 adult patients. *Acta Neurochirurgica*. 2005;147(11):1151–1155.
  12. Cheng KJ, Wang SQ, Lin L. Giant osteomas of the ethmoid and frontal sinuses: clinical characteristics and review of the literature. *Oncology Letters*. 2013;5(5):1724–1730.
  13. Vishwakarma R, Joseph ST, Patel KB, Sharma A. Giant frontal osteoma: case report with review of literature. *Indian Journal of Otolaryngology and Head & Neck Surgery*. 2011;63:122–126.
  14. Layadi F, Aniba K, Lmejhati M, Aït Elqadi A, Aït Benali S. Giant osteoid osteoma of the posterior skull base. A case report and literature review. *Neurochirurgie*. 2006;52:128–132.
  15. Das AK., Kashyap RC. Osteoma of the mastoid bone—a case report. *Medical Journal Armed Forces India*. 2005;61(1):86–87.
  16. Panjwani S, Bagewadi A, Keluskar V, Arora S. Gardner's syndrome. *Journal of Clinical Imaging Science*. 2011;1:65.
  17. Guérin N, Chauveau E, Julien M, Dumont JM, Merignargues G. Osteoma of the mastoid bone: report of two cases. *Revue de Laryngologie Otolologie Rhinologie*. 1996;117(2):127–132.
  18. Gungor A, Cincik H, Poyrazoglu E, Saglam O, Candan H. Mastoid osteomas: report of two cases. *Otology and Neurotology*. 2004;25(2):95–97.
  19. El Fakiri M, El Bakkouri W, Halimi C, Aït Mansour A, Ayache D. Mastoid osteoma: report of two cases. *European Annals of Otorhinolaryngology, Head and Neck Diseases*. 2011;128(5):266–268.
  20. Greenspan A. Benign bone-forming lesions: osteoma, osteoid osteoma, and osteoblastoma: clinical, imaging, pathologic, and differential considerations. *Skeletal Radiology*. 1993;22(7):485–500.
  21. Gungör A, Cincik H, Poyrazoglu E, Saglam O, Candan H. Mastoid osteomas: report of two cases. *Otology and Neurotology*. 2004;25(2):95–97.
  22. Kieffer AS, Long DM, Chou NS, King GA, Cacayorin ED. Tumors of the skull. *Neurological Surgery*. Philadelphia, Pa, USA: WB Saunders; 1990. pp. 3599–3601.
  23. Hirokawa M, Manabe T, Hino K. Ampullary carcinoma in Gardner's syndrome: case report. *Jpn. J. Clin. Oncol*. 1988;18(1): 43-50.
  24. Newman CA, Reuther WL, Wakabayashi MN. Gastrointestinal case of the day. Gardner syndrome. *Radiographics*. 19(2): 546-548.
  25. Denia A, Perez F, Canalis RR., Graham MD. Extracanalicular osteomas of the temporal bone. *Archives of Otolaryngology*. 1979;105(12):706–709.
  26. Probst LE, Shankar L, Fox R. Osteoma of the mastoid bone. *Journal of Otolaryngology*. 1991;20(3):228–230.
  27. Ben-Yaakov A, Wohlgeleirnter J, Gross M. Osteoma of the lateral semicircular canal. *Acta Oto-Laryngologica*. 2006;126(9):1005–1007. doi: 10.1080/00016480500527292.
  28. Birrell JF. Osteoma of the mastoid. *Journal of the Royal College of Surgeons of Edinburgh*. 1978;23(5):305–309.
  29. Smud D, Augustin G, Kekez T, Kinda E, Majerovic M, Jelincic Z. Gardner's syndrome: genetic testing and colonoscopy are indicated in adolescents and young adults with cranial osteomas: a case report. *World Journal of Gastroenterology*. 2007;13(28):3900–3903.