

---

## ANATOMICAL CROWN-ROOT-RATIO: A PROXY TO ROOT LENGTH DETERMINATION IN RURAL ENDODONTIC PRACTICE

MADUKWE I.U.

*\*Department of Surgery and Pathology, Department of Dentistry,  
University of Benin, Benin City, Nigeria*

---

### ABSTRACT

**Background:** Power supply has become increasingly erratic. In the rural communities it may be completely lacking, making radiography impossible. Tooth multiplication factor is a viable option to periapical radiographs in endodontic treatment.

**Methodology:** A total of 120 upper central permanent incisor teeth were selected from 2,765 extracted teeth used for teaching of oral biology to dental students. These teeth were collected over 10-year period. The permanent central incisors were sorted using size, shape, colour and specific central incisor indices as parameter. Tooth location to the left or right was not of prime importance.

Anatomical root-crown-ratio was determined using calibrated card board paper, simple ruler and Vernier calipers. One hundred and twenty upper permanent central incisors were randomly divided into six groups (A to F) before measurement of crown and root lengths.

**Result:** Crown-root-ratio was 1:1.375. Every millimeter of crown is equal to 1.375mm of root. Where (x) is the crown length. Therefore an anatomical crown length of 10mm will have an endodontic root length of 13.75mm given a total canal length of 23.75mm which is in tandem with reported average maxillary central incisors average canal length of 22mm – 23.8mm

**Conclusion:** Tooth multiplication factor is recommended for trial especially in this power situation, especially worse in rural communities.

### INTRODUCTION

Crown-root-ratio is the ratio of the length of the part of a tooth that appears above the alveolar bone versus what lies below it. It is an important consideration in the diagnosis, treatment planning and restoration of teeth. It is a primary variable in the diagnosis of a tooth as an abutment for the various types of prosthetic restorations, such as fixed dental prostheses or removable partial dentures or over dentures<sup>1-3</sup>. Root-crown-ratio is the value between root and crown and may be classified as the anatomical or the clinical. Root-crown ratio is defined by the alveolar bone level and provides information on the alveolar support. This is determined radiographically.<sup>4</sup> This study is on the anatomical-root-crown-ratio of extracted upper central incisors teeth, used for the teaching of oral biology to dental students.

### Materials and Methods

A total of 120 upper central permanent incisor teeth were selected from 2,765 extracted teeth (Fig.1) in the Department of Oral Surgery and Pathology collected for the teaching of oral biology to Dental Students. These teeth were preserved in 10% formalin bottle (in line with Centre for Disease Control and Prevention Guideline for infection control) used for research and teaching.<sup>5-6</sup>

These teeth were collected over 10-year period and the permanent central incisors were sorted using central incisors' anatomical key features of medio-incisal and disto-incisal angles of 90° single root. Three labial lubrication lines and in addition size, shape, colour and specific central incisor tooth indices as parameter. Tooth location to the right or left was not of prime importance. Mamelons were excluded because they are easy worn off with age. Anatomical root-crown ratio was determined using calibrated

---

Corresponding Author: MADUKWE I.U.  
Department of Surgery and Pathology  
Faculty of Dentistry, University of Benin,  
Benin City, Nigeria.  
E-mail: madukwe236@yahoo.com

card board paper with ruler (fig 2) and Vernier calipers. One hundred and twenty upper permanent central incisors were randomly divided into six groups before (A to F) before measurement of crown and root length of each tooth in the groups. Teeth with cervical pathologies were excluded to avoid spacioussness.

#### Result:



Fig 1.2,765 extracted teeth

#### Discussion

Dentists' awareness that natural teeth function more efficiently than the artificial ones has continuously raises the quest for prudent saving of pulpally compromised teeth. This is through endodontic therapy, of which determination of working length is imperative. This working length determination is usually through tactile method, electronic apex locator or radiographic methods in vivo. This study ex-vivo on 120 extracted human permanent upper central incisors, which established X(1.375)mm as a multiplication factor where (x) is the crown length and the product is the root length.

Similar studies were done by Shanmugaraj et al 2007 using tactile method, Formation-IV digital electronic apex locators and radiograph method. This was compared with working length in an extracted teeth. Electronic apex locators showed the highest accuracy and highest reliability to ex-vivo anatomical crown root ratio.<sup>7</sup> On the contrary

Table 1: Anatomical Crown and Root Lengths of randomly divided 120 upper permanent central incisor teeth in groups of 20

S/N	Groups	Crown Length in mm	Root Length in mm
1.	A	209	274.5
2.	B	200	271
3.	C	202	261.5
4.	D	189	282
5.	E	189	272
6.	F	201	275.5
<b>Total</b>		<b>1,190</b>	<b>1,636.5</b>

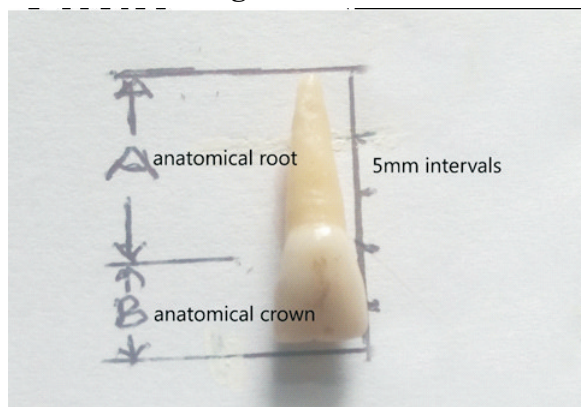
$$\text{Crown-Root-Ratio} = 1636.5/1190 = 1:1.375 = 1.375$$

Every millimeter of crown length = 1.375 millimeters of Root length.

Root length = x (1.375) mm.

Where x = crown length.

**Fig 2: showed an upper central incisors mounted on a calibrated paper with crown length of 10mm.**



Applying  $\times(1.375)$ mm multiplication factor gives a product of  $10(1.375)$ mm = 13.75mm root length; making a total canal length of 23.75mm.

Mohan and Anand posit that electronic apex locators are not superior to radiographic methods in determining working length of root canal, but no comparison with the working length in extracted ex-vivo teeth.<sup>8</sup> Haghanifar et al in their in-vivo study of crown-root ratio in permanent maxillary central incisor teeth revealed a crown-root ratio of 1:1.710, and standard deviation 0.36; confidence interval of 1.63 - 1.79.<sup>9</sup> This is in conformity with our ex-vivo findings of 1:1.375 from fig 2 results  $10(1.375)$  gives 13.75mm root length making a canal length of  $(10 + 13.75)$  23.75mm which is slightly at variance with Caucasian values of 21-22.5mm average canal length<sup>10</sup> but in tandem with reported African average maxillary central incisors average canal length of 22mm-23.8mm by Abiodun-Solankeet al 2013 and Okpo and Akpata 1986 findings.<sup>11-12</sup>

### Conclusion

We therefore conclude that in this era of epileptic power supply and lack of electricity in the rural communities, this multiplication factor will be proxy to estimation of root length, which is pre-requisite for endodontic practice. We recommend it for rural endodontic practice bearing in mind that save natural tooth is of better clinical use to the patient than artificial one.

### References:

1. Grossmann Y, sadan A. the prosthetic concept of crown root ratio : A review of the literature . J . prosthetic Dent (2005 ) 93 (6): 559 562
2. Schedule J, f loves A. M, weed M. crown to implant ratios of singles tooth implant supported restoration j. prosthetic Den (2007), 98 (1):1-5
3. Nissan J, ghelfan O, Gross O, Priell, gross M, Chanshu G, The Effect Of Crown Implant Ratio And Crown Height Space On Stress Distribution in Unsplinted Implant Supporting Restoration J. oral maxillofacial surgery (2011) 67(7) 1934 1939.
4. Penny RE, Kraal JH. Crown-to-root ratio. Its significance in restorative dentistry. /. Prosthet. Dent. 1979; 42: 34-38.
5. Kumar M., Sequeira PS, Bhat GK. Sterilization of extracted human teeth for educational use. Indian Jour. Med. Micro. 2005; 23(4): 256-8.
6. Lee JJ, Nettey-Morbell A, Cook A. Jr., Pimeta LA, Leon and R, Ritter AV. Using extracted teeth for research: The effect of storage medium and sterilization on dentin bond strength. J. American Dental. Assoc. 2007 Dec., 138(12): 599-603.
7. ShanmugarajM., Nivedha R., Mathan R., Balogopal S. Evaluation of working length determination methods: An in-vivo / ex-vivo study. Indian J. Dent. Res. 2007 April-June; 18(2): 60-2.
8. Mohan MG, Anand VS. Accuracy of different methods of working length determination in endodontics, 2013; Jour. Deut. Medic. Sc. 12(4): 25-38.
9. Haghanifar S, Moudi E, Abbasi S, Bijami A, Mir APB, Ghasemi N. Root-crown Ratio in permanent dentition using panoramic radiography in a selected Iranian Population 2014; /. Dent. (Shiraz) Dec; 1514), 173-179.
10. Carrotte P. Endodontics; Part 4 morphology of Root Canals system British Dental Journal (2004)197,379

- 383.
11. Abiodun solanke IMF , Ajayi DM, Abu A.O endodontic treatment of unusually long discolored central Incisors ; a case report Ann Ib Postgraduate Med. 2013 ; 11(1) 37-40
  12. Okpo E, Akpata E. tooth Lengths in Nigerians Int. Endo J 1986; 19 :248 252.